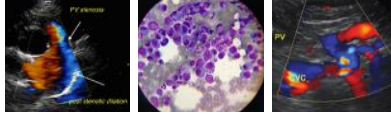


IMAGING PERFORMED BY

IntraPet.com



Clinical Sonography & Telecytology

EDUCATIONAL TELECONSULTATION SERVICES™

1-800-838-4268 info@sonopath.com SonoPath.com

PATIENT

Nala Collison

SPECIES

Feline

BREED

DSH

SEX

Female Spayed

AGE

5.21.13

WEIGHT

9.5lbs

INTERPRETED BY

Maggie Machen Lamy,
DVM, DACVIM
(Cardiology)

HOSPITAL NAME

Northwind Animal
Hospital

REFERRING VET

Dr. Cross

INVOICE

31842

DATE

7.13.23

PRESENTING CLINICAL SIGNS

History: Grade 3/6 heart murmur diagnosed in 2020. PE otherwise unremarkable.

-Pertinent abnormal PE/Chem/CBC/UA Results: Largely NSF.

-Current medications: None.

-Sedation used: Patient sedated with Torbugesic.

-Pertinent previous ultrasound results: No previous.

-STAT: Not requested

-Imaging performed by: Andi Parkinson, BS, RDMS.

ECHOCARDIOGRAM FINDINGS

2D, m-mode, color flow and doppler imaging is available. The left ventricular wall is largely normal in dimension with a borderline focal septal thickening. There is a mildly hyperechoic endocardium consistent with fibrosis and remodeling. Papillary muscles appear remodeled. The left atrium is borderline normal in size. The right atrium is normal in size. The right ventricle appears normal. No TR. The mitral valve is normal in structure and mobility with trace MR. Blood flow through the RVOT is normal in velocity. Blood flow through the LVOT is mildly elevated with a dynamic profile. There is no pleural or pericardial effusion seen. There are no obvious cardiac tumors.

CARDIAC CHART

FELINE CARDIAC PARAMETERS	BODY WEIGHT (kg)	HR (BPM)	IVSd (cm) <small>(Moise, Pipers)</small>	LVIDd (cm) <small>(Moise, Pipers)</small>	LWVd (cm) <small>(Moise, Pipers)</small>	FS (%)	EF (%)
NORMAL PARAMETER	-----	150-240	3.5-0.55	<2 (mean 1.5)	3.5-0.55	35-67	80-100
PATIENT	4.3	NM	0.56	1.2	0.43	55	88
FELINE CARDIAC PARAMETERS	LA/AO <small>(Boon)</small>	LA/AO HEART BASE (Swe) <small>(Abbott)</small>	LA 2D short axis Base view (cm) <small>(Abbott)</small>		LVOT VEL (m/s)	RVOT VEL (m/s)	E max (m/s)
NORMAL	<1.5	<1.3	<1.2		<1.6	<1.3	<0.9
PATIENT	NM	1.3	1.2		2.5	1.3	NM

Adapted from June Boon, Veterinary Echocardiography, 1998
Abbott J & MacLean H JVIM 2006;20: 111-119, Moise et al. Am J Vet Res 47:1476, 1986. Pipers et al. Am J Vet Res 40:882, 1979.

INTERPRETATION OF THE FINDINGS & FURTHER RECOMMENDATIONS

The cause of the murmur is an LVOT obstruction. This is secondary to a borderline focal bulge. Regardless, the overall LV wall dimensions are normal with no clear hypertrophic component at this time. These findings may represent early HOCM; however, there is a subset of cats with a dynamic LVOT obstruction that is stress-related and does not lead to secondary LVH or LA dilation (LA is borderline normal in this case). Serial echocardiography will be necessary to determine progression and clinical relevance of findings.

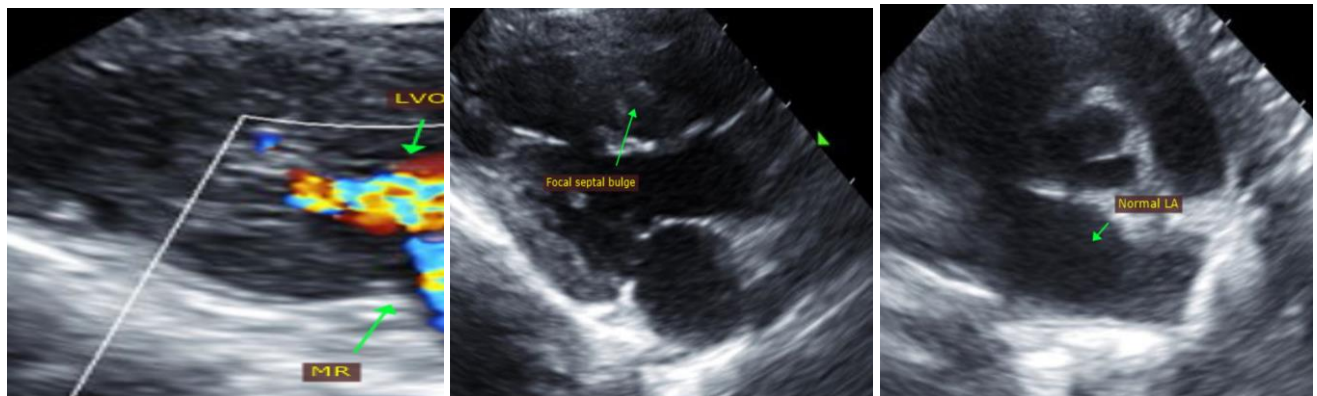
Should LVH or LA dilation develop in the future, a beta blocker may be indicated to lower heart rate and decrease the pressure gradient. Based upon what is seen here, this is not clearly indicated at this time. A screening BP and T4 are recommended every 6 months going forward, as either issue may exacerbate disease.

Monitor for any clinical signs associated with progression, including increased RR/RE, syncope or signs of a blood clot (paralysis, neurologic change, etc.).

Anesthetic risk is currently low; however, the ECG must be evaluated prior to proceeding. Avoid heart rate stimulating drugs (atropine, glycopyrrolate) unless clinically necessary. Avoid vasodilators such as acepromazine as this can worsen obstruction. Judicious IV fluid rates are recommended to avoid fluid overload in this patient with diastolic dysfunction.

A recheck echocardiogram is recommended in 6 months to assess for progression, sooner if any clinical signs arise.

IMAGES



The information and recommendations provided are based on the images presented by the referring veterinarian. No evaluation can be communicated regarding pathology that was not visible in the image/video clips provided.

Thank you for this referral. This report was generated using transcription software, and minor dictation errors may be present. If the clinical or image interpretation does not parallel your findings or if I can be of any further assistance, please contact me.

Maggie Machen Lamy, DVM
Diplomate of the American College of Veterinary Internal Medicine (Cardiology)
info@sonopath.com